



Characterization and potential of Pigeon Pea; *Cajanus cajan* L. Mill sp. Phytoestrogen on rat ovary

Cicilia Novi Primiani^{1*}, Pujiati Pujiati¹, Sutiman B. Sumitro²

¹PGRI Madiun University, Madiun, East Java, Indonesia, ²Department of Biology, Faculty of Mathematics and Natural Sciences, Brawijaya University, Malang, East Java, Indonesia

Corresponding Author:

Cicilia Novi Primiani
Jalan Setia Budi No. 85,
Kartoharjo, Madiun, East Java,
Indonesia.
Phone +62-351-462986.
Fax. +62-351-459400.
Email: primiani@unipma.ac.id

Received: June 2018

Accepted: November 2018

Published:

ABSTRACT

Objectives: The objective of this study was to analyze the estrogenic compounds in pigeon pea seeds and the effect of the plant seeds to rat ovaries development. **Materials and Methods:** The *Cajanus cajan* seeds were extracted, and to elucidate its content, liquid chromatography-mass spectrometry (LC-MS), and gas chromatography (GC)-MS analysis were employed. 24 Sprague-Dawley female rats were divided into three experimental groups and feed with *C. cajan* solution. The experimental groups were: P₀ (control/without *C. cajan* solution), P₁ (24 g:24 ml), and P₂ (8 g:24 ml). The experimental treatment by *C. cajan* was for 36 days. On the 37th day, rats were dissected to examine the ovary and liver organs. **Results:** Based on LC-MS analysis, it was obtained that *C. cajan* seeds contain several phytoestrogens. GC-MS analysis showed that *C. cajan* seeds contain up to 7.91945 µg/kg of 17β-estradiol. The observations showed a normal liver tissue structure, and there is no necrosis identified in the lobules of the hepatic sinusoids. The ovarian tissue structure of rats in the P₀ treatment group appeared normal. Some germinal follicular developments were detected in ovarian tissue of P₁ and P₂ treatment groups. **Conclusion:** *C. cajan* shows potential as a natural estrogenic substance that is effective and safe for further application in human hormone replacement therapy.

Keywords: *Cajanus cajan*, follicle ovarium, phytoestrogen

INTRODUCTION

Hormone use carries many therapeutic health benefits. For instance, estrogen can be used for cardiovascular treatment, menopause postponement, osteoporosis prevention, and cancer treatment.^[1-4] Estrogen hormone therapy (hormone replacement therapy or HRT) typically uses synthetic hormones because they are considered to be effective and efficient. In this instance, however, the long-term risks associated with their use have not been extensively considered.^[5,6]

Phytoestrogens or plant-derived estrogens may be a safer alternative to synthetic hormones. Several plants have been studied to be used as a natural source of ingredients for HRT. Among them, phytoestrogen-rich *Pueraria mirifica* can be used to prevent bone loss.^[7] Pollens of *Pinus yunnanensis* (Franch.) are proven to decrease the risk of premature ovarian failure. Phytoestrogens can be used to alleviate the lack of estrogen in body.^[8] Yam tubers (*Pachyrhizus erosus*) (400 and 800 mg/kg) are affirmed to prevent bone loss in ovariectomized rats, as

a model for osteoporosis prevention.^[9] Furthermore, *P. erosus* (0.9 g/kg) leads to a proliferation of uterine endometrial glands, and proliferation and maturation of ovarian follicles in premenopausal rats.^[10] In addition, yam tuber juice is clinically proven to cause a proliferation of myometrium tissue, increasing the thickness of rat myometrium.^[11]

In general, phytoestrogens, under certain circumstances, show some of the same activities as human female estrogen, although they have a weaker effect. However, phytoestrogens are more effective than their synthetic counterparts and thus, maybe a suitable alternative for use in human HRT. Furthermore, exposure to phytoestrogens has a longer effect and considered safer than the synthetic as the side effects from the synthetic are not observed in phytoestrogen treatment.^[12-16] One potential source of the natural phytoestrogen hormone, estrogen, is pigeon pea (*Cajanus cajan*). *C. cajan* (Indonesian local name *kacang gude*) belongs to the Fabaceae or Leguminosae family and cultivated in many developing countries in the semi-arid tropics and subtropics. The roots contain genistein and

genistin.^[17] *C. cajan* also contains chemical properties, such as daidzein and the lignan, secoisolariciresinol diglucoside.^[18] *C. cajan* leaves are rich in flavonoids and stilbenes. They also contain saponins, tannins, and moderate amounts of resins, reducing sugars, and terpenes. *C. cajan* leaf extract is shown to decrease uterine contractions in rats^[19] and increase the childbirths rate.^[20]

The application of *C. cajan* as a natural replacement for synthetic estrogen has not been widely investigated. In this context, the current study aimed to identify and quantitate the phytoestrogens present in pigeon pea (*C. cajan*) seeds and the influence of the seeds on the development of germinal ovarian follicles in rats.

MATERIALS AND METHODS

Materials

Dried *C. cajan* seeds were obtained from several pigeon pea plantations in Ponorogo and Madiun, Indonesia.

Sample Preparation

First, the dried *C. cajan* seeds were washed and dried to remove any unwanted debris. Next, they were mashed with a blender and initial total weight of the seeds between 100 and 250 g. The pre-weighed, finely-ground seeds were then placed in 95% methanol at a 1:5 ratio (sample: methanol). The mixture was homogenized, put into sealed bottles, and allowed to stand for 24 h at low temperature. Then, the solution was filtered using an Erlenmeyer vacuum filter. This treatment was repeated 3 times.

The combined filtrates were evaporated using a rotary evaporator, to remove the methanol until a semi-viscous extract was obtained (the solution obtained was half the volume of the original filtrate). After that, the extract was diluted with methanol to obtain 100 ppm concentration and homogenized. The extract was centrifugated in 8000 rpm for 10 min to separate the solid matter. The supernatant was taken for protein precipitation by adding 3 ml acetonitrile, which acidified by 0.2% formic acid, to 2 ml of supernatant. The solution was then centrifuged in 8000 rpm for 30 s. Finally, the supernatant was taken for the next step analysis.

Extract Purification

The extract was then purified using solid phase extraction using C18 Sep-pak. The cartridge for the C18 column was conditioned by pouring 95% methanol (up to 2 column volumes) into the column to obtain an eluate. Then, a solution of acidified distilled water (3 column volumes) was poured in to obtain eluate as the remaining methanol was removed. Next, the liquid extract was poured into the cartridge until color development in the cartridge was apparent. Usually, the poured sample volume was between 5- and 10 ml, which was later put into the C18 column containing 360 mg of sorbent. Next, the extract was eluted with 95% methanol and then rotary evaporated at 40°C under reduced pressure to remove the methanol. The eluate was re-dissolved using acidified distilled water or an aliquot of the liquid chromatography-mass spectrometry (LC-MS) mobile

phase. The purified extract was stored at 4°C for no >24 h. For longer storage, it was kept at -15°C or lower (-70°C recommended) in a frost resistance bottle.

LC-MS Analysis

The method of LC-MS was used by Konar *et al.*,^[21] Konar *et al.*,^[22] and Hanganu *et al.*^[23] The samples were injected into the LC-MS system and then analyzed with LC-MS manufacturer based on the manufacturer procedure (Shimadzu, Japan).

17 β -Estradiol Analysis

The 17 β -estradiol analysis on *C. cajan* seeds using gas chromatography (GC)-MS based on the manual procedure.^[24] The specification for the GC-MS is as follow: (1) FID Detector; (2) Shimadzu stainless steel column 30 m \times 0.25 mm; (3) 250°C inlet temperature; (4) 300°C detector temperature; (5) carrier gas nitrogen; (6) 2 ml/min flow rate; (7) 2 μ l injection volume; and (8) 25 min runtime analysis based on Janeczko and Skoczowski.^[25]

Experimental Animals

A total of 24 female Sprague-Dawley rats aged between 6 and 7 months and weighing 150–180 g were obtained from laboratory animal farms in Blitar, Indonesia. The animals were placed in a group cage located in the Bioscience laboratory at Brawijaya University, Indonesia.

The room temperature ($\pm 27^\circ\text{C}$) was carefully maintained with 50-60% relative humidity and 12-h lighting cycle. The rats were fed with milk pellet, which contained 12% water, 16% crude protein, 3-7% crude lipid, 8% crude fiber, 10% ash, 0.9-1.2% calcium, and 0.6-1% phosphorus, with yellow corn as the main source. It also contained wheat bran, soybean meal SBM, palm oil, essential amino acids, essential minerals, premix, and vitamins. The laboratory animals were maintained according to the experimental animal guide of the Institute of Biosciences, Brawijaya University. The procedures were approved by Brawijaya University Ethics Committee, with ethical clearance no. KEP-168-UB.

Treatment Groups

The rats were grouped into three treatment groups: (1) The first group was control (P_0) group, fed by food pellets; (2) the second group was fed with *C. cajan* solution extract at a ratio of 24 g *C. cajan* powder: 24 ml distilled water (P_1); and (3) the third group was fed with *C. cajan* solution 8 g *C. cajan* powder: 24 ml distilled water (P_2). The dose extract was based on our previous study, which observed significant growth in ovarian follicle after 20,188 mg/100g daidzein administration for 36 days.^[26] The *C. cajan* solution was administered by gavage into the rat stomach using a gastric tube every morning for 36 days. Based on high-performance LC analysis, the P_1 solution contained 29.77580 $\mu\text{g/ml}$ daidzein and 40.45506 $\mu\text{g/ml}$ genistein compounds, while P_2 contained daidzein and genistein compounds, at 12.19308 $\mu\text{g/ml}$ and 18.71281 $\mu\text{g/ml}$, respectively.

Histopathological Analysis

On the 37th day, all the rats were dissected to collect the ovary and liver organs for examination. Histological sections were

prepared according to standard paraffin slide procedures.^[24] The samples were fixated in Bouin solution; dehydrated in alcohol series (50%, 70%, 85%, and 96%, and absolute); cleaned in alcohol: xylol solution; infiltrated and embedded in paraffin; and finally sliced in 12 μ m thickness. The sliced paraffin-tissues were stained by Hematoxylin-Eosin. The histopathological changes in structure were observed using optical microscopy Obtilab twice for each organ. The observation results were then confirmed by experts.

Data Analysis

The analysis of pigeon pea compounds containment was based on the chromatogram. The data analysis of ovarian and liver tissue structure was drawn on the observation using optical microscopy. The obtained data were not statistically analyzed as the data were chromatography and histological data.

RESULTS AND DISCUSSION

C. cajan Compounds

From the LC-MS spectrum results [Figure 1] of the *C. cajan* seeds, 35 chemical properties were identified [Table 1]. Some of the isoflavones identified were daidzein, genistein, glycitein,

daidzein, genistin, glycitin, malonyl daidzein, malonyl genistin, and malonyl glycitin. This group of phytoestrogens is structurally similar to estrogen. The phytoestrogens are structurally similar to 17 β -estradiol. Hence, they are commonly referred to as estrogen-like-molecules. Some estrogen-like compounds are the isoflavonoids (genistein, daidzein, biochanin A, and formononetin), flavonoids (chrysin, apigenin, naringenin, kaempferol, and quercetin), coumestans (coumestrol, 4-methoxycoumestrol), and lignans (enterolactone, enterodiol, matairesinol, and secoisolariciresinol diglucoside).^[27,28]

β -Estradiol in *C. cajan* Seeds

The GC-MS results of the *C. cajan* seeds [Table 2] showed that the hormone, 17 β -estradiol, was present up to 7.91945 mg/kg. The 17 β -estradiol hormone is a steroid hormone in mammals. In this regard, it supports the theory that 17 β -estradiol, androsterone, progesterone, and testosterone are present in 60-80% of 128 plant species investigated.^[25]

Histopathological Observation of Rat Ovaries and Liver

The ovarian tissue structure of rats in the P₀ treatment group appeared normal. In the cortex, epithelium, tunica albuginea,

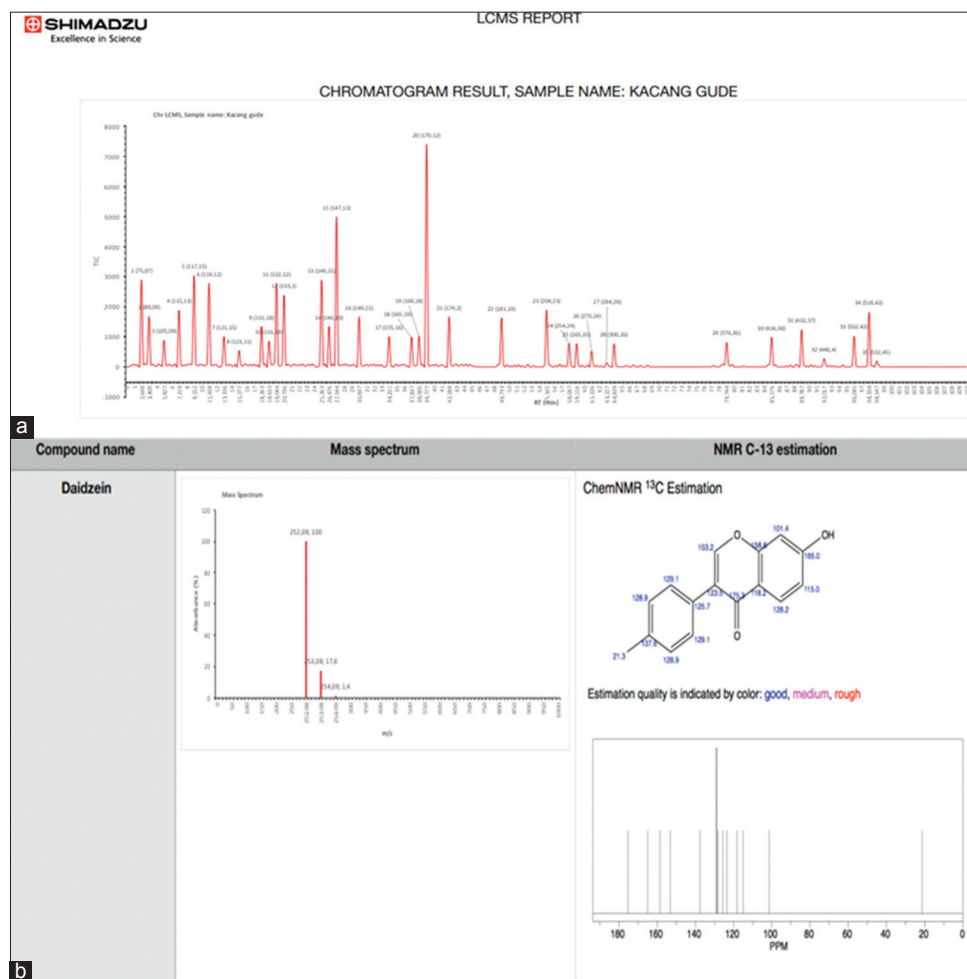


Table 1: LC-MS results of *Cajanus cajan* seeds analysis

No.	Composition	Molecular weight (g/mol)	Name compound	No.	Composition	Molecular weight (g/mol)	Name compound
1.	5,002	75.07	Glycine	19.	1,772	169.18	Pyridoxine
2.	2,892	89.09	Alanine	20.	12,816	170.12	Gallic acid
3.	1,523	105.05	Serine	21.	2,879	174.20	Arginine
4.	3,255	115.13	Proline	22.	2,813	181.19	Tyrosine
5.	5,247	117.15	Valine	23.	3,269	204.23	Tryptophan
6.	4,809	119.12	Threonine	24.	1,339	254.24	Daidzein*
7.	1,738	121.15	Cysteine	25.	1,330	265.35	Thiamine
8.	0,932	123.11	Niacin	26.	0,906	270.24	Genistein*
9.	2,316	131.18	Isoleucine	27.	0,224	284.26	Glycitein*
10.	1,476	131.18	Leucine	28.	1,322	300.26	Cajanine
11.	4,804	132.12	Asparagine	29.	1,405	376.36	Riboflavin
12.	4,116	133.10	Aspartic acid	30.	1,702	416.38	Daidzein*
13.	4,987	146.15	Glutamine	31.	2,127	432.37	Genistin*
14.	2,316	146.19	Lysine	32.	0,471	446.40	Glycitin*
15.	8,641	147.13	Glutamic acid	33.	1,764	502.42	Malonyl daidzein*
16.	2,879	149.21	Methionine	34.	3,137	518.42	Malonyl genistin*
17.	1,736	155.16	Histidine	35.	0,327	532.45	Malonyl glycitin*
18.	1,712	165.19	Phenylalanine				

*Member of phytoestrogens. LC-MC: Liquid chromatography-mass spectrometry

Table 2: Results of GCMS 17 β estradiol analysis on *Cajanus cajan*

Sample name	Sample weight (g)	RT (min)	Sample curve area	Result ($\mu\text{g/kg}$)	compound
Pigeon pea	2,008	12,469	1,429,255	7,91945	17 β -estradiol

GCMS: Gas chromatography-mass spectrometry

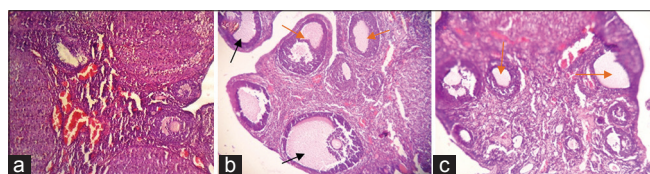


Figure 2: The rats ovarian tissue structure, H and E staining, $\times 100$. (a) Control, (b) *Cajanus cajan* seeds solution treatment at 24 g: 24 ml (P_1), (c) *C. cajan* seeds solution treatment at 8 g: 24 ml (P_2). (a) The germinal follicle germ has not undergone any maturation process, (b) The germinal experienced growth and maturation, follicle Graaf (black arrowhead) showed some follicular fluid, (c) the germinal follicle experienced growth although not extensive, some primary and secondary follicles (orange arrowhead) were shown

and follicles were observed [Figure 2a]. In the ovarian tissue of the P_1 and P_2 rat treatment groups, some germinal follicular developments were noticed. Secondary follicle and follicle de Graaf were mainly found in the P_1 and P_2 ovarian tissue compared to control. Meanwhile, numerous germinal follicle was observed in control but not follicle de Graaf [Figure 2b and c]. Primary follicles of the P_1 rats were not highly visible because they had already developed and matured into secondary follicles and Graafian follicles. Graafian follicles (or vesicular ovarian follicles) are fluid-filled cavities that surround and protect the developing oocyte in mammalian

ovaries.^[29-31] Moreover, the cortex layer structure of the P_1 rats had undergone some proliferation [Figure 2b]. The primary follicles of the P_2 rats seemed to have spread. Any considerable growth or maturation was not detected in the follicles. Several secondary follicles were identified, but Graafian follicles were not present yet.

The ovary has estrogen receptors (ERs).^[32,33] Estrogenic compounds, such as those identified in *C. cajan* (genistein, daidzein, glycitein, genistin, daidzein, glycitin, malonyl genistin, malonyl daidzein, and malonyl glycitein) have a similar structure to estrogen that binds to the ERs in the ovaries. Isoflavones, namely, daidzein, genistein, and glycitein, are structurally similar to 17 β -estradiol^[34-36] and can be found in the Fabaceae plant family.

The chemical structure of phytoestrogens found in *C. cajan* has a potentially similar structure to the estrogen hormone. Phytoestrogens that bind to ERs *in vivo* result in an increased level of the estrogen hormone in the blood.^[37-40] The level of estrogenic compounds in the blood is increased by the presence of 17 β -estradiol hormone, resulting in growth and maturation of ovarian germinal follicles.^[41,42] The *C. cajan* seed estrogenic compounds may change the structure of ovarian tissue, based on our observation. Phytoestrogens have a strong binding affinity with the ERs, although it is much weaker than that of estradiol. Isoflavones exert estrogenic effects on a number

of target organs that possess ER α and/or ER β , although the binding affinities of isoflavones with these receptors are much lower than those of 17 β -estradiol.^[43] Phytoestrogen compounds *Cajanus cajan* has an activity similar estrogen, can be absorbed in the blood with low levels, and can be excreted through the urine.^[44-46]

The observations showed a normal liver tissue structure, and the lobules of the hepatic sinusoids appeared clean; there were no changes identified. Cylindrical liver lobule surrounds the central vein that flows into the hepatic venous and then flows into the vena cava. No necrosis was identified in the liver tissue structure. The microscopic observations of the paraffin section revealed that normal hepatic sinusoid and hepatic lobules could be clearly identified in the liver tissue [Figure 3]. The liver is a multifunctional organ which has a pivotal role in human metabolism, especially in detoxification. One of the signs of toxicity is the damage in the hepatocytes.^[47-49] As observed in the histological slide, the *C. Cajan* extract was not induce any toxicity in the given concentration; thus, it will not harm the body in overall.

Phytoestrogens compounds are multi-component and multi-targeted since they have multiple ERs.^[50] Multi-compounds phytoestrogens ingested soy protein are biotransformed by intestinal microflora, are absorbed, undergo enterohepatic recycling.^[51] *C. cajan* has a multi-compound, could get into circulation and then be metabolized.^[52] Moreover, these compounds may have metabolic interaction, stabilize the interaction within the body. The complexity of *C. Cajan* pea compounds may interact with each other and then to the body system. The complex interaction has better potential than a single active compound. The *C. cajan* seeds solution did not promote any structural changes in the liver tissue. Multi-compound *C. cajan* is able to have synergy with body system. Consequently, *C. cajan* can be applied as a natural estrogen, providing its safety in humans is investigated.^[53-55]

CONCLUSION

Based on LCMS analysis, *C. cajan* seeds contain compounds, such as daidzein, genistein, glycitein, daidzein, genistin, glycitin,

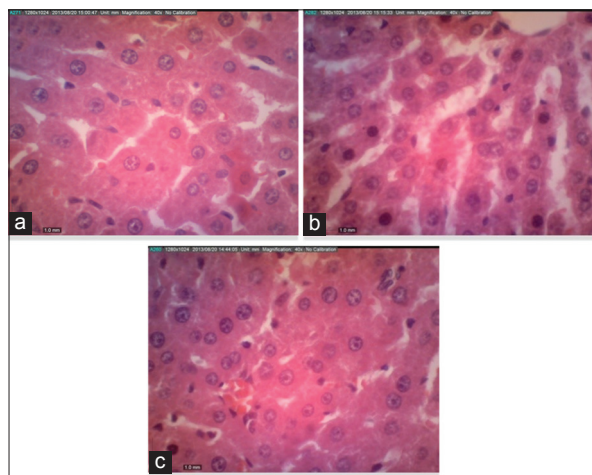


Figure 3: Hepatocytes structure of rats, H and E staining, $\times 400$. (a) Control (P₀), (b) *Cajanus cajan* seeds solution treatment at 24 g:24 ml (P₁), (c) *C. cajan* seeds solution treatment at 8 g:24 ml (P₂)

malonyl daidzein, malonyl genistin, and malonyl glycitin. According to GCMS analysis, *C. cajan* seeds contain 7.91945 mg/kg of 17 β -estradiol. In summary, *C. cajan* shows potential as a natural estrogenic substance that is effective and safe.

ACKNOWLEDGMENTS

The researcher would like to thank the Head of LPPM University of PGRI Madiun for providing and entrusting the researcher to conduct this research and seminar. Thank you as well to Ministry of Research, Technology and Higher Education of Indonesia (Kementerian Riset, Teknologi, dan Pendidikan Tinggi Republik Indonesia) for supporting in research funding.

REFERENCES

1. Indian J Exp Biol Glazier MG, Bowman MA. A review of the evidence for the use of phytoestrogens as a replacement for traditional estrogen replacement therapy. Arch Intern Med 2001;161:1161-72.
2. Manson JE, Martin KA. Clinical practice. Postmenopausal hormone-replacement therapy. N Engl J Med 2001;345:34-40.
3. Katalinic A, Rawal R. Decline in breast cancer incidence after decrease in utilisation of hormone replacement therapy. Breast Cancer Res Treat 2008;107:427-30.
4. Schierbeck LL, Rejnmark L, Tofteng CL, Stilgren L, Eiken P, Mosekilde L, et al. Effect of hormone replacement therapy on cardiovascular events in recently postmenopausal women: Randomised trial. BMJ 2012;345:e6409.
5. Cirigliano M. Bioidentical hormone therapy: A review of the evidence. J Womens Health (Larchmt) 2007;16:600-31.
6. de Villiers TJ, Gass ML, Haines CJ, Hall JE, Lobo RA, Pierroz DD, et al. Global consensus statement on menopausal hormone therapy. Climacteric 2013;16:203-4.
7. Urasopon N, Hamada Y, Asaoka K, Cherdshewasart W, Malaivijitnond S. *Pueraria mirifica*, a phytoestrogen-rich herb, prevents bone loss in orchidectomized rats. Maturitas 2007;56:322-31.
8. Ye MH, Zhou B, Liu ZH, Shi LH, Wang T, Yin LD, et al. Studies on the protective effects of pollen-originated phytoestrogens on the growth and development of ovary in rats. J Med Plants Res 2012;6:3732-41.
9. Nurrochmad A, Leviana F, Wulancarsari CG, Lukitaningsih E. Phytoestrogens of *Pachyrhizus erosus* prevent bone loss in an ovariectomized rat model of osteoporosis. Int J Phytomed 2010;2:367-72.
10. Primiani CN. The phytoestrogenic potential of yam bean (*Pachyrhizus erosus*) on ovarian and uterine tissue structure of premenopausal mice. Biol Med Nat Prod Chem 2015;4:5-9.
11. Primiani CN, Lestari U, Amin M, Sumitro S. Comparative study of effects daidzein contained in yam tuber *Pachyrhizus erosus* and pure daidzein; the dynamics of chemical compounds and its potential in myometrium. J Biol Res 2014;18:1-7.
12. Yoo HH, Kim T, Ahn S, Kim YJ, Kim HY, Piao XL, et al. Evaluation of the estrogenic activity of leguminosae plants. Biol Pharm Bull 2005;28:538-40.
13. Calixto JB. Efficacy, safety, quality control, marketing and regulatory guidelines for herbal medicines (*Phytotherapeutic agents*). Braz J Med Biol Res 2000;33:179-89.
14. Carusi D. Phytoestrogens as hormone replacement therapy: An evidence-based approach. Prim Care Update OB/GYNS 2000;7:253-9.
15. Cos P, De Bruyne T, Apers S, Vanden Berghe D, Pieters L, Vlietinck AJ, et al. Phytoestrogens: Recent developments. Planta Med 2003;69:589-99.
16. Cederroth CR, Zimmermann C, Nef S. Soy, phytoestrogens and their impact on reproductive health. Mol Cell Endocrinol

- 2012;355:192-200.
17. Sarkar R, Hazra B, Mandal N. Anti-oxidative protection against iron overload-induced liver damage in mice by *Cajanus cajan* (L.) millsp. Leaf extract. Indian J Exp Biol 2013;51:165-73.
18. Mazur W, Adlercreutz H. Naturally occurring oestrogens in food. Pure and applied chemistry 1998;70:1759-1776.
19. Olatunji-Bello II, Obijeh TA, Mojiminiyi FB. Tocolytic effect of *Cajanus cajan* (in-vitro studies using the rat uterus). Niger Q J Hosp Med 2010;10:279-81.
20. Olayaki LA, Olatunji-Bello I, Soladoye AO, Jimoh OR, Ghaza O, Ighodalo M. Effects of aqueous leaf extract of *Cajanus cajan* on litter size and serum progesterone in pregnant rats. J Pharm Phytother 2009;1:21-4.
21. Konar N, Poyrazoglu ES, Demir K, Artik N. Determination of conjugated and free isoflavones in some legumes by LC-MS/MS. J Food Comp Anal 2012;25:173-8.
22. Konar N, Poyrazoglu ES, Demir K, Artik N. Effect of different sample preparation methods on isoflavone, lignan, coumestan and flavonoid contents of various vegetables determined by triple quadrupole LC-MS/MS. J Food Comp Anal 2012;26:26-35.
23. Hanganu D, Vlase L, Olah N. LC/MS analysis of isoflavones from *Fabaceae* species extracts. Farmacia 2010;58:177-83.
24. Cui L, Zhou QF, Liao CY, Fu JJ, Jiang GB. Studies on the toxicological effects of PFOA and PFOS on rats using histological observation and chemical analysis. Arch Environ Contam Toxicol 2009;56:338-49.
25. Janeczko A, Skoczowski A. Mammalian sex hormones in plants. Folia Histochem Cytobiol 2005;43:71-9.
26. Primiani CN. Dinamika Bahan Aktif Kompleks Daidzein Dalam Umbi Bengkuang (*Pachyrhizus erosus*) Pada Tikus Putih Betina Sebagai Bahan Penyusun Buku Saintifikasi Jamu. Thesis and PhD dissertation: State Malang University; 2014.
27. Nilsson S, Mäkelä S, Treuter E, Tujague M, Thomsen J, Andersson G, et al. Mechanisms of estrogen action. Physiol Rev 2001;81:1535-65.
28. Pilšáková L, Riečanský I, Jagla F. The physiological actions of isoflavone phytoestrogens. Physiol Res 2010;59:651-64.
29. Gougeon A. Regulation of ovarian follicular development in primates: Facts and hypotheses. Endocr Rev 1996;17:121-55.
30. Norris DO, Lopez KH. The endocrinology of the mammalian ovary. In: Hormones and Reproduction of Vertebrates: Mammals. USA: University of Colorado; 2011. p. 59-72.
31. Rajkovic A, Pangas SA, Matzuk MM. Follicular development: Mouse, sheep, and human models. Knobil Neill's Physiol Reprod 2006;1:383-424.
32. Palter SF, Tavares AB, Hourvitz A, Veldhuis JD, Adashi EY. Are estrogens of import to primate/human ovarian folliculogenesis? Endocr Rev 2001;22:389-424.
33. Belcher SM, Zsarnovszky A. Estrogenic actions in the brain: Estrogen, phytoestrogens, and rapid intracellular signaling mechanisms. J Pharmacol Exp Ther 2001;299:408-14.
34. Adams NR. Detection of the effects of phytoestrogens on sheep and cattle. J Anim Sci 1995;73:1509-15.
35. Sosvorova L, Lankova P, Bucikova M, Prokudina EA, Maharik NA, Lapčík O. ELISA for free S-equol in human urine. Czech J Food Sci 2011;29:57-64.
36. He FJ, Chen JQ. Consumption of soybean, soy foods, soy isoflavones and breast cancer incidence: Differences between Chinese women and women in Western countries and possible mechanisms. Food Sci Hum Wellness 2013;2:146-61.
37. Patisaul HB, Jefferson W. The pros and cons of phytoestrogens. Front Neuroendocrinol 2010;31:400-19.
38. Mueller SO, Simon S, Chae K, Metzler M, Korach KS. Phytoestrogens and their human metabolites show distinct agonistic and antagonistic properties on estrogen receptor alpha (ERalpha) and ERbeta in human cells. Toxicol Sci 2004;80:14-25.
39. Turner JV, Agatonovic-Kustrin S, Glass BD. Molecular aspects of phytoestrogen selective binding at estrogen receptors. J Pharm Sci 2007;96:1879-85.
40. Kostelac D, Rechkemmer G, Briviba K. Phytoestrogens modulate binding response of estrogen receptors alpha and beta to the estrogen response element. J Agric Food Chem 2003;51:7632-5.
41. Silva P, Rocha MJ, Cruzeiro C, Malhão F, Reis B, Urbatzka R, et al. Testing the effects of ethinylestradiol and of an environmentally relevant mixture of xenoestrogens as found in the Douro river (Portugal) on the maturation of fish gonads – a stereological study using the zebrafish (*Danio rerio*) as model. Aquat Toxicol 2012;124-125:1-0.
42. Jefferson WN, Couse JF, Padilla-Banks E, Korach KS, Newbold RR. Neonatal exposure to genistein induces estrogen receptor (ER) alpha expression and multioocyte follicles in the maturing mouse ovary: Evidence for ERbeta-mediated and nonestrogenic actions. Biol Reprod 2002;67:1285-96.
43. Kim SH, Park MJ. Effects of phytoestrogen on sexual development. Korean J Pediatr 2012;55:265-71.
44. Dai Q, Franke AA, Jin F, Shu XO, Hebert JR, Custer LJ, et al. Urinary excretion of phytoestrogens and risk of breast cancer among Chinese women in Shanghai. Cancer Epidemiol Biomarkers Prev 2002;11:815-21.
45. Zheng W, Dai Q, Custer LJ, Shu XO, Wen WQ, Jin F, et al. Urinary excretion of isoflavonoids and the risk of breast cancer. Cancer Epidemiol Biomarkers Prev 1999;8:35-40.
46. Grace PB, Taylor JI, Low YL, Luben RN, Mulligan AA, Botting NP, et al. Phytoestrogen concentrations in serum and spot urine as biomarkers for dietary phytoestrogen intake and their relation to breast cancer risk in European prospective investigation of cancer and nutrition-norfolk. Cancer Epidemiol Biomarkers Prev 2004;13:698-708.
47. Mahli H, Gores GJ, Lemaster JJ. Apoptosis and necrosis in the liver: A tale of death? Hepatology 2006;43:S31-44.
48. Ernawati M, Wiwik D. Effect of halotan air exposure with subanesthesia dose to liver disorder of mice. J Sains Teknol Farmasi 2006;11:71-5.
49. Brzóska MM, Moniuszko-Jakoniuk J, Piłat-Marcinkiewicz B, Sawicki B. Liver and kidney function and histology in rats exposed to cadmium and ethanol. Alcohol Alcohol 2003;38:2-10.
50. Sirotkin AV, Harrath AH. Phytoestrogens and their effects. Eur J Pharmacol 2014;741:230-6.
51. Setchell KD. Phytoestrogens: The biochemistry, physiology, and implications for human health of soy isoflavones. Am J Clin Nutr 1998;68:1333S-1346S.
52. Qiao X, Ye M, Xiang C, Wang Q, Liu CF, Miao WJ, et al. Analytical strategy to reveal the in vivo process of multi-component herbal medicine: A pharmacokinetic study of licorice using liquid chromatography coupled with triple quadrupole mass spectrometry. J Chromatogr A 2012;1258:84-93.
53. Zava DT, Blen M, Duwe G. Estrogenic activity of natural and synthetic estrogens in human breast cancer cells in culture. Environ Health Perspect 1997;105 Suppl 3:637-45.
54. Williamson EM. Synergy and other interactions in phytomedicines. Phytomedicine 2001;8:401-9.
55. Permender R, Hema C, Sushila R, Dharmender R, Vikash K. Antidiabetic potential of *Fabaceae* family: An overview. Curr Nutr Food Sci 2010;6:161-75.